Journal of Pediatric Surgery 58 (2023) 1430–1434

Contents lists available at ScienceDirect

Journal of Pediatric Surgery

journal homepage: www.sciencedirect.com/journal/journal-of-pediatric-surgery

Initial Outcomes Using Cryoablation in Surgical Management of Slipping Rib Syndrome

Krista Lai, R Scott Eldredge, Melissa Nguyen, Benjamin E. Padilla, Lisa E. McMahon*

Division of Pediatric Surgery, Phoenix Children's Hospital, Phoenix, AZ, USA

ARTICLE INFO

Article history:
Received 24 June 2022
Received in revised form
16 December 2022
Accepted 29 December 2022

Keywords:
Slipping rib syndrome
Cryoablation
Cartilaginous rib excision

ABSTRACT

Introduction: Minimally invasive repair of pectus excavatum (MIRPE) and cartilaginous rib excision (CRE) for slipping rib syndrome (SRS) are painful procedures. Intercostal nerve cryoablation (Cryo) controls pain and decreases opioid use in MIRPE. Herein, we describe our experience with cryoablation in CRE.
Methods: A retrospective chart review was performed of all patients undergoing CRE between 2018 and 2022. Data on demographics, clinical characteristics, operative details, and hospital course were collected.
Results: A total of 98 patients underwent CRE: 68 CRE without cryo, 22 CRE + Cryo, and 8 combined MIRPE + CRE + Cryo. Ninety percent of patients underwent bioabsorbable rib plating. Patients were predominantly female (79%, 73%, 50% respectively) with median ages 17.6, 16.9, and 14.2 years respectively. CRE + Cryo patients used significantly less opioids in hospital (0.6 OME/kg [0.1,1.2]) compared to CRE without cryo (1.0 OME/kg [0.6,2.1]), $p < 0.05$. The median length of stay (LOS) in CRE + Cryo was 1 day [1,2] compared to 2 days in CRE without cryo [1,2], $p = 0.09$. MIRPE + CRE + Cryo patients used 0.6 OME/kg [0.2,8.0] with a 2 day [1,5.5] LOS. Ninety-one percent of Cryo patients had cryoablation of T9 and/or T10 intercostal nerves, with no documented abdominal wall laxity at median follow-up of 16 days. Cryo was applied extra-thoracically in CRE + cryo without thoracoscopy or lung isolation, while MIRPE + CRE + Cryo used a combination extra-/intra-thoracic cryoablation in with thoracoscopy.
Conclusion: Intercostal nerve cryoablation reduces opioid use and LOS in patients undergoing cartilaginous rib excision for slipping rib syndrome. Cryotherapy to as low as T10 did not result in abdominal wall laxity and can be applied extra-thoracically without the need for thoracoscopy. Ongoing prospective studies are required to assess the long-term outcomes.
Level of evidence: III.

© 2023 Elsevier Inc. All rights reserved.

1. Introduction

Slipping rib syndrome (SRS) is characterized by pain from impingement of intercostal nerves caused by hypermobile anterior false ribs (8th-10th) slipping under or abutting the rib above [1]. This occurs from weakness in the interchondral ligaments [2]. Similar symptoms can occur in the floating ribs 11 and 12. The pain from SRS ranges from intermittent, sharp, stabbing, or popping to dull and burning. It can also be misinterpreted as abdominal pain [3] due to convergence of the lower intercostal nerves and abdominal visceral sympathetic nerves [1]. Treatment begins with conservative measures including activity modifications, ice, NSAIDs, and topical analgesics. More intensive therapy consists of interventions such as rib blocks, manipulative techniques, acupuncture, and sometimes opioids [4]. Cartilaginous rib excision (CRE) is recommended for those who fail conservative treatment and has been shown to provide effective and durable pain relief [1].

CRE is performed through a small incision at the lower costal margin to identify the detached, hypermobile cartilaginous ribs, taking care to stay out of the thoracic cavity. The cartilaginous rib, sometimes including the perichondrium, is excised to the costochondral junction, leaving the bony rib intact [1,4,5]. The neurovascular bundle associated with the rib is isolated and preserved. Existing literature largely reports successful pain relief following

Abbreviations: CRE, Cartilaginous rib excision; Cryo, Intercostal nerve cryoablation; LOS, Length of stay; MIRPE, Minimally invasive repair of pectus excavatum; OME, Oral morphine equivalent; SRS, Slipping rib syndrome; VAS, Visual analog scale.

* Corresponding author at: Pediatric Surgeon, 1919 E Thomas Road, Phoenix, AZ, 85016, USA.

E-mail addresses: kristalai90@gmail.com (K. Lai), lmcmahon@phoenixchildrens.com (L.E. McMahon).

https://doi.org/10.1016/j.jpedsurg.2022.12.031
0022-3468/© 2023 Elsevier Inc. All rights reserved.

CRE [1,4]. However, little data exists regarding the postoperative pain management following CRE.

Intercostal nerve cryoablation (Cryo) is used for analgesia during the minimally invasive repair of pectus excavatum (MIRPE). The cyoprobe is applied thoracoscopically to deliver extremely cold temperature to intercostal nerves to temporarily disrupt nerve function [6]. Cryoablation during MIRPE decreases postoperative opioid use and hospital length of stay (LOS) [7–9]. In this study, we report the outcomes of expanding the use of Cryo to CRE procedures.

2. Methods

2.1. Collection and analysis

With institutional board review approval (IRB 17–098), a retrospective chart review was performed for patients ≤18yo undergoing CRE from January 2018 to March 2022. Three groups of patients were identified for comparison: CRE without cryo, CRE + Cryo, and CRE + MIRPE + Cryo. Data on demographics, operative procedure, hospital course, and postoperative complications were collected. Groups were compared using the Kruskal–Wallis test for continuous variables and the Pearson Chi-square test or Fisher's exact test for categorical variables. Multivariant analysis was performed on continuous variables. Parameter estimate β was reported with $P < 0.05$ considered statistically significant. Statistical analysis was performed using PASW Statistics for Windows, Version 18 (Chicago: SPSS Inc.).

2.2. Technique

CRE was performed as previously described [10]. Slipping ribs were localized by physical exam and dynamic ultrasound. Incisions overlying these areas were made and the hypermobile cartilaginous ribs identified. The cartilaginous ribs, including perichondrium, were excised to the costochondral junction, preserving the intercostal neurovascular bundle. Efforts were made to avoid violating the parietal pleura. Vertical rib plating was performed using bioabsorbable plates (Poly-L/DL Lactide 70:30 blend; Biobridge™, Acute Innovations, Hillsboro, OR) to prevent possible slipping of the bony rib following resection of the slipping cartilaginous rib [10].

Cryo was performed using the Cyrosphere2 (AtriCure, Mason, OH) probe. The probe was applied to the intercostal neurovascular bundle and cooled to −60 °C for 2 min, followed by an active rewarming phase to 4 °C before removing the probe from contact with tissue. For combined CRE + MIRPE cases, Cryo was performed intra-thoracically under thoracoscopic visualization with lung isolation when the intercostal level was accessible; intercostal nerves 4–7 were cryoablated for MIRPE. For the lower ribs undergoing CRE, Cryo was performed extra-thoracically by tunneling the probe submuscularly to access the intercostal nerve from outside of the chest cavity. While protecting skin from the cold shaft of the cryoablation probe, the probe is tunneled along the inferior border of the remaining bony rib and placed several centimeters posterior-lateral to the incision edge (Fig. 1). For CRE operations without MIRPE, Cryo was applied extra-thoracically without lung isolation or insertion of a thoracoscope.

Preoperatively, most patients received a nerve block by anesthesiology. Postoperatively, all patients received multi-agent analgesia including scheduled acetaminophen and ibuprofen, and oxycodone as needed. Early ambulation was encouraged, and restrictions were limited to avoidance of heavy lifting and twisting with weight.

3. Results

In total, 98 patients were identified – 68 CRE without cryo, 22 CRE + Cryo, and 8 CRE + MIRPE + Cryo. Demographics are shown in Table 1. Median ages ranged from 14.2 years to 17.6 years ($p < 0.05$) and patients were predominantly female. Operatively, most patients underwent bilateral rib excisions. Significant differences were noted between groups in operative time and total number of ribs excised (Table 1).

Table 2 summarizes the use of differing pain control modalities across groups. The CRE + MIRPE + Cryo group had greater total number of nerves cryoablated (13.5 [9.3,14]) compared to the CRE + Cryo group (6 [4,8]) ($p < 0.05$). A similar proportion of patients in the CRE + Cryo group (91%) had cryoablation to low-level (T9 and/or T10) nerves compared to CRE + MIRPE + Cryo (88%) ($p = 0.78$). Rates of PCA, epidural, and elastomeric pain pump use were similar between groups. Opioid use in the CRE + MIRPE + Cryo (0.17 OME/kg/day [0.03,1.3]) and the CRE + Cryo groups (0.42 OME/kg/day [0.1,0.7]) was significantly less than the CRE without cryo (0.60 OME/kg/day [0.4,1.0]) group. When comparing CRE without cryo to CRE + Cryo, there remained a significant difference in total opioid use (1.0 OME/kg [0.6,2.1] vs. 0.6 OME/kg [0.1,1.2], $p < 0.05$) and total opioid use per day (0.6 OME/kg/day [0.4,1.0] vs. 0.4 OME/kg/day [0.1,0.7], $p < 0.05$). Multivariate analysis was performed to evaluate the covariates associated with decreased total opioid use and decreased total opioid use per hospital day. The CRE + Cryo and CRE + MIRPE + Cryo were both associated with decreased opioid use compared to CRE without cryo ($\beta = -0.25$, 95% CI [−0.43, −0.07]; $P < 0.05$) when controlling for other factors. The number of cartilaginous ribs resected ($\beta = 0.08$, 95% CI [−0.18, 0.18]; $p = 0.37$), unilateral vs bilateral cartilage resection ($\beta = 0.32$, 95% CI [−0.67, 1.31]; $p = 0.922$) and use of rib plating ($\beta = -0.08$, 95% CI [−0.44, 0.27] $p = 0.472$), along with age ($\beta = 0.01$, 95% CI [−0.03, 0.05]; $p = 0.40$), gender ($\beta = 0.17$, 95% CI [−0.34, 0.68]; $p = 0.81$), and BMI ($\beta = -0.02$, 95% CI [−0.05, 0.01]; $p = 0.363$) were not associated with differences in in-hospital opioid use.

Median visual analog scale (VAS) pain scores were similar across groups (Table 2). CRE + Cryo patients had a 1-day shorter LOS ($p < 0.05$) compared to the other 2 groups. However, when comparing CRE without cryo to CRE + Cryo, there was no significant difference in LOS ($p = 0.09$). Postoperative emergency department visits were observed in all groups: 4 (5.9%) patients from CRE

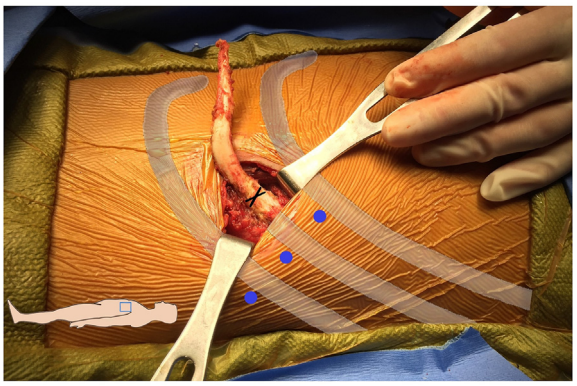

Fig. 1. The cartilaginous rib depicted is rib number 9 following dissection. The rib is excised to the costochondral junction (X). The overlying ribs represent the undissected cartilaginous ribs 8 and 10 in anatomic position. Extra-thoracic cryoablation (dot) is performed by tunnelling the probe submuscularly, along the inferior border of the remaining bony rib, several centimeters from the posterior-lateral incision edge. Image orientation is indicated by the drawing in the bottom left.

Table 1
Demographics and operative characteristics.

	CRE without cryo	CRE + Cryo	CRE + MIRPE + Cryo	p-value
Age at operation, years	17.6 [15.9,19.8]	16.9 [15.9,18.6]	14.2 [13.7,16.6]	<0.05
Biological sex, n (%)				0.18
Female	54 (79.4)	16 (72.7)	4 (50)	
Male	14 (20.6)	6 (27.3)	4 (50)	
BMI, kg/m^2	20.9 [19.1,23.6]	20.2 [17.8,24.4]	18.4 [16.2,21.8]	0.26
Operative time, minutes	126.5 [100,148]	142.5 [104,182]	218.5 [209,269]	<0.05
Laterality of rib excision, n (%)				0.26
Unilateral	22 (32.4)	11 (50)	2 (25)	
Bilateral	46 (67.6)	11 (50)	6 (75)	
Total # ribs excised	4 [3,5]	2 [2,4]	3.5 [2.3,4.8]	<0.05
Median # ribs excised/side	2 [2,3]	2 [1,3]	2 [1,3]	0.12
Patients w/vertical rib plating, n (%)	59 (87)	22 (100)	7 (88)	0.19

Values expressed in median [IQR 25,75] unless otherwise indicated.

without cryo, 3 (13.6%) from CRE + Cryo, and 1 (12.5%) from CRE + MIRPE + Cryo (p = 0.19). Likewise, a small number of patients were hospitalized in the CRE without cryo (2.9%), CRE + Cryo (4.5%), and CRE + MIRPE + Cryo (12.5%) groups (p = 0.16). There was no abdominal wall laxity or weakness reported in Cryo patients at 2-week follow-up (median 16 days [IQR 9, 25]). No patients had postoperative wound infections or pneumothoraces requiring chest tube insertion.

4. Discussion

In this patient cohort, Cryo was used successfully for post-operative analgesia in patients undergoing CRE for slipping rib syndrome. We first applied Cryo in the setting of CRE in patients undergoing concurrent MIRPE for pectus excavatum, as Cryo was already being performed for MIRPE and the Cryo field was expanded to include T8-T10. Good pain control and no abdominal wall laxity with Cryo to the lower intercostal nerves was noted, therefore Cryo was subsequently applied to all patients undergoing CRE. Compared to CRE without cryo, the CRE + Cryo patients used significantly less opioid while hospitalized.

These findings mirror the reported experiences of using Cryo for MIRPE in the setting of pectus excavatum, where Cryo has been shown to decrease inpatient opioid use and LOS [7,8]. In a recent large series of MIRPE performed by a single surgeon, 65 Cryo patients were compared to 119 non-Cryo. The Cryo patients used 76% less opioid in hospital compared to the non-Cryo (1.2 OME/kg [0.7–1.9] vs. 5.0 OME/kg [3.5–6.6]) with a 2-day shorter median length of day (2 days [1,2] vs. 4 days [3,5]) [7]. Furthermore, a prospective randomized controlled trial demonstrated that Cryo was superior to thoracic epidural in the setting of MIRPE, with 60% less overall in-hospital opioid use and 2 day shorter LOS [9].

In our practice we routinely excise 2–3 cartilaginous ribs per affected side, which has been borne out in other's experience with 3 cartilaginous ribs commonly excised [4]. Bilateral SRS is well reported in the literature with rates of bilateral CRE in 16–84% of patients [1,4,10]. Investigators who report low rates of bilateral SRS at time of initial CRE also report SRS symptom development on the contralateral chest in 21% of patients [4]. Given the risk of contralateral SRS symptom development our patients routinely undergo bilateral dynamic ultrasound as part of diagnostic workup [1]. Often bilateral disease is found with patients reporting bilateral symptoms. Patients are counseled on the risks and benefits of synchronous bilateral CRE. In the current series, bilateral CRE was performed in 64% of patients with SRS. Although CRE without Cryo had more total number of ribs resected, the median number of ribs resected per side across all groups was 2 ribs. To evaluate whether the number of cartilaginous ribs excised and/or bi-vs uni-laterality were important determinants of opioid use, a multivariate regression analysis was performed. The number of ribs excised and bilaterality were not important determinants of postoperative in-hospital opioid utilization. Whether 1 or 4 cartilaginous ribs are resected unilaterally or bilaterally, the patient stands to benefit from cryotherapy.

VAS scores were similar between the non-Cryo and Cryo groups, demonstrating that pain was well controlled in all patients. However, adequate pain control was achieved in the Cryo group using significantly less opioid. The goal of Cryo was to control post-operative pain, while sparing opioid use, and to this end Cryo was successful. Another reason for equivalent VAS across groups may be owing to the frequent delays in diagnosing SRS, leading to chronic pain prior to presenting for surgical intervention [2,4]. The timing of resolution of chronic pain associated with SRS and resolution of post-operative pain from CRE is unknown. Although this study did not evaluate opioid use following discharge from CRE, we believe that Cryo has the potential for decreasing opioid use following discharge as return of sensation to the chest wall takes up to 1 year [9,11]. While Cryo may incur higher material/equipment costs, there are significant safety benefits to minimizing pediatric opioid use that must be taken into the cost-benefit analysis [12,13]. Tracking post discharge opioid use and analgesia requirements would be an important next step in quantifying the full benefit of Cryo.

Table 2
Clinical outcomes.

	CRE without cryo	CRE + Cryo	CRE + MIRPE + Cryo	p-value
Total # of nerves cryoablated bilaterally	n/a	6 [4,8]	13.5 [9.3,14]	<0.05
Number of patients with low-level[a] nerves cryoablated bilaterally	n/a	20 (90.9)	7 (87.5)	<0.05
Total opioid use, OME/kg	1.0 [0.6,2.1]	0.6 [0.1,1.2]	0.6 [0.2,8.0]	<0.05
Total opioid use per day, OME/kg/day	0.6 [0.4,1.0]	0.42 [0.1,0.7]	0.17 [0.03,1.3]	<0.05
Discharge opioid prescription, OME/kg	3.4 [2.5,4.2]	2.9 [2.4,3.6]	3.6 [2.7,5.0]	0.10
VAS pain score	4.9 [4.0,6.1]	4.8 [3.8,6.0]	3.6 [2.5,5.4]	0.16
Time with VAS >7, minutes	60 [0,461.8]	0 [0,413.8]	30 [0,751.5]	0.63
LOS, days	2 [1,2]	1 [1,2]	2 [1,5.5]	<0.05

[a] Low-level is T9 and/or T10; OME – oral morphine equivalent.

There was a low rate of complications in this study, including postoperative pneumothoraces. Lung isolation to prevent inadvertent contact between the cryoablation probe and lung parenchyma was employed in the combined MIRPE + CRE cases. When Cryo was applied only extra-thoracically in the CRE + Cryo cases, no thoracoscopy or lung isolation were used and no lung injury was noted in this study cohort. This suggests the degree of coldness achieved on the parietal pleural surface when applying Cryo extra-thoracically is not sufficient to injure the visceral pleural. Moreover, there was no reported abdominal wall laxity or weakness, as assessed by the patient's ability to get up from a supine position without the use of their upper extremities, among Cryo patients at a median follow-up time of 16 days. The sensory changes to the chest wall, as evident by decreased opioid use and chest wall numbness, are apparent within a day of the operation. Given that the mechanism of axonal degeneration is the same for sensory and motor neurons, we would expect any motor deficits to manifest in the same time frame [6]. The intercostal nerves are predominantly sensory nerves, with approximately 40% motor fibers [14]. Temporary loss of intercostal nerve motor function does not appear to have any significant impact on motor function of breathing because of its selective regional activation [15]. However, the manufacturer of the cryoablation probe cautions against cryoablating below the 9th intercostal space due to the risk of abdominal wall laxity and weakness, as the intercostal nerves below T9 provide some motor innervation to the abdominal wall musculature [16]. Given the redundancy in motor innervation of the abdominal wall musculature, it is likely that temporary loss in intercostal nerve motor function is compensated for innervation from other nerve roots. Additionally, in the extra-thoracic anterior location of cryoablation for this procedure (Fig. 1), the sensory lateral cutaneous branch is likely most affected; at the angle of the rib, this branch pierces through intercostal muscles to lie more superficially [17,18]. We believe that motor dysfunction resulting from cryoablation would have manifested by the median follow-up of 16 days, as the mechanism of sensory and motor denervation with cryoablation is the same and sensory changes are evident within 1 day of the nerve freezing [19]. While abdominal wall laxity was not encountered in this patient group, it merits further longer-term study.

The long-term effects of cryoablation are also an area requiring ongoing investigation. Cryoablation temporarily disrupts nerve function through extremely cold temperatures leading to axonotmesis and subsequent downstream Wallerian degeneration [6]. However, at temperatures of −20 °C to −100 °C, the fibrous neural sheath surrounding the nerve remains intact, allowing axonal regeneration that occurs over weeks to months [20]. While there is no prospective data regarding return of sensation, retrospective data in children who underwent Cryo during MIRPE has demonstrated that majority have resolution of numbness by 3–4 months [11,21]. In particular, a randomized-control trial of 20 patients who underwent MIRPE, with 10 receiving Cryo, reported 100% return of sensation at 1-year post-procedure [9]. Neuropathy is also another potential side effect of Cryo that is an active area of investigation. Zobel et al. [11] reported no neuropathic pain in 30 patients ≤21 years old who underwent MIRPE + Cryo, while another retrospective series of 65 pediatric patients reported 6% experienced allodynia with 100% resolution at 1 year [7].

There are limitations inherent in the single-center retrospective nature of this study that limits generalizability. With the use of other pain control modalities (albeit similar rates between groups) the full extent of analgesic impact of cryoablation is likely not captured. As part of our practice, patients routinely received a regional nerve block in the form of erector spinae, paravertebral, and/or intercostal nerve blocks. Given the variability in the permutations of the assorted regional blocks, the cohort was analyzed as a whole group. One of the short comings of the study is that we cannot assess whether certain regional blocks might confer pain control benefits that are comparable to the effects seen with cryoablation. Long-term pain and sensation outcomes are not assessed by the follow-up duration. Abdominal wall bulging was also determined subjectively by the patient and the surgeon.

5. Conclusion

SRS is a painful condition where surgery is often the final modality of treatment after exhausting conservative measures. Cryoablation at the time of CRE decreased opioid use and hospital length of stay postoperatively. Cryoablation can be safely performed extra-thoracically without the need for lung isolation or thoracoscopy. Prospective studies are warranted to gauge its full impact and track long-term sensory and motor outcomes.

Funding

This research did not receive any specific grant from funding agencies in the public, commercial, or not-for-profit sectors.

Declaration of Competing Interest

Benjamin E Padilla is a consultant for AtriCure.

References

[1] McMahon LE. Slipping Rib Syndrome: a review of evaluation, diagnosis and treatment. Semin Pediatr Surg 2018;27(3):183–8. https://doi.org/10.1053/j.sempedsurg.2018.05.009.
[2] Foley Davelaar CM. A clinical review of slipping rib syndrome. Curr Sports Med Rep 2021;20(3):164–8. https://doi.org/10.1249/JSR.0000000000000821.
[3] Mooney DP, Shorter NA. Slipping rib syndrome in childhood. J Pediatr Surg 1997;32(7):1081–2. https://doi.org/10.1016/s0022-3468(97)90403-6.
[4] Fraser JA, Briggs KB, Svetanoff WJ, St Peter SD. Long-term outcomes and satisfaction rates after costal cartilage resection for slipping rib syndrome. J Pediatr Surg 2021;56(12):2258–62. https://doi.org/10.1016/j.jpedsurg.2021.01.034.
[5] Fu R, Iqbal CW, Jaroszewski DE, St Peter SD. Costal cartilage excision for the treatment of pediatric slipping rib syndrome. J Pediatr Surg 2012;47(10):1825–7. https://doi.org/10.1016/j.jpedsurg.2012.06.003.
[6] Zhou L, Kambin P, Casey KF, Bonner FJ, O'Brien E, Shao Z, et al. Mechanism research of cryoanalgesia. Neurol Res 1995;17:307–11.
[7] Sun RC, Mehl SC, Anbarasu CR, Portuondo JI, Espinoza AF, Whitlock R, et al. Intercostal cryoablation during Nuss procedure: a large volume single surgeon's experience and outcomes. J Pediatr Surg 2021;56(12):2229–34. https://doi.org/10.1016/j.jpedsurg.2021.03.006.
[8] Parrado R, Lee J, McMahon LE, Clay C, Powell J, Kang P, et al. The use of cryoanalgesia in minimally invasive repair of pectus excavatum: lessons learned. J Laparoendosc Adv Surg Tech 2019;29(10):1244–51. https://doi.org/10.1089/lap.2019.0203.
[9] Graves CE, Moyer J, Zobel MJ, Mora R, Smith D, O'Day M, et al. Intraoperative intercostal nerve cryoablation during the Nuss procedure reduces length of stay and opioid requirement: a randomized clinical trial. J Pediatr Surg 2019;54(11):2250–6. https://doi.org/10.1016/j.jpedsurg.2019.02.057.
[10] McMahon LE, Salevitz NA, Notrica DM. Vertical rib plating for the treatment of slipping rib syndrome. J Pediatr Surg 2021;56(10):1852–6. https://doi.org/10.1016/j.jpedsurg.2020.09.062.
[11] Zobel MJ, Ewbank C, Mora R, Idowu O, Kim S, Padilla BE. The incidence of neuropathic pain after intercostal cryoablation during the Nuss procedure. Pediatr Surg Int 2020;36(3):317–24. https://doi.org/10.1007/s00383-019-04602-1.
[12] Harbaugh CM, Gadepalli SK. Pediatric postoperative opioid prescribing and the opioid crisis. Curr Opin Pediatr 2019;31(3):378–85. https://doi.org/10.1097/MOP.0000000000000768.
[13] Mazer-Amirshahi M, Mullins PM, Rasooly IR, van den Anker J, Pines JM. Trends in prescription opioid use in pediatric emergency department patients. Pediatr Emerg Care 2014;30(4):230–5. https://doi.org/10.1097/PEC.0000000000000102.
[14] Nguyen KD, Choudhri HF, Macomson SD. The intercostal nerve as a target for diagnostic biopsy. J Neurosurg 2018;128(4):1222–5. https://doi.org/10.3171/2016.12.JNS152565.
[15] De Troyer A, Kirkwood PA, Wilson TA. Respiratory action of the intercostal muscles. Physiol Rev 2005;85(2):717–56. https://doi.org/10.1152/physrev.00007.2004.

[16] cryoICE® cryoSPHERE™ cryoablation probe [instructions for use]. Mason, OH: Atricure, Inc. https://www.atricure.com/sites/default/files/devices-ifu/IFU-0036.A.pdf. Accessed May 18, 2022.
[17] Bijkerk E, Cornelissen AJM, Sommer M, Van Der Hulst RRWJ, Lataster A, Tuinder SMH. Intercostal nerve block of the anterior cutaneous branches and the sensibility of the female breast. Clin Anat 2020;33(7):1025–32. https://doi.org/10.1002/ca.23532.
[18] Gardner ED, Bunge RP. Chapter 2: gross anatomy of the peripheral nervous system. In: Dyck PJ, Thomas PK, editors. Peripheral neuropathy. 4th ed. Saunders; 2005. p. 11–33.
[19] Evans PJD. Cryoanalgesia: the application of low temperatures to nerves to produce anaesthesia or analgesia. Anaesthesia 1981;36(11):1003–13.
[20] Ilfeld BM, Finneran JJ. Cryoneurolysis and percutaneous peripheral nerve stimulation to treat Acute pain. Anesthesiology 2020;133(5):1127–49. https://doi.org/10.1097/ALN.0000000000003532.
[21] Graves C, Idowu O, Lee S, Padilla B, Kim S. Intraoperative cryoanalgesia for managing pain after the Nuss procedure. J Pediatr Surg 2017;52(6):920–4. https://doi.org/10.1016/j.jpedsurg.2017.03.006.